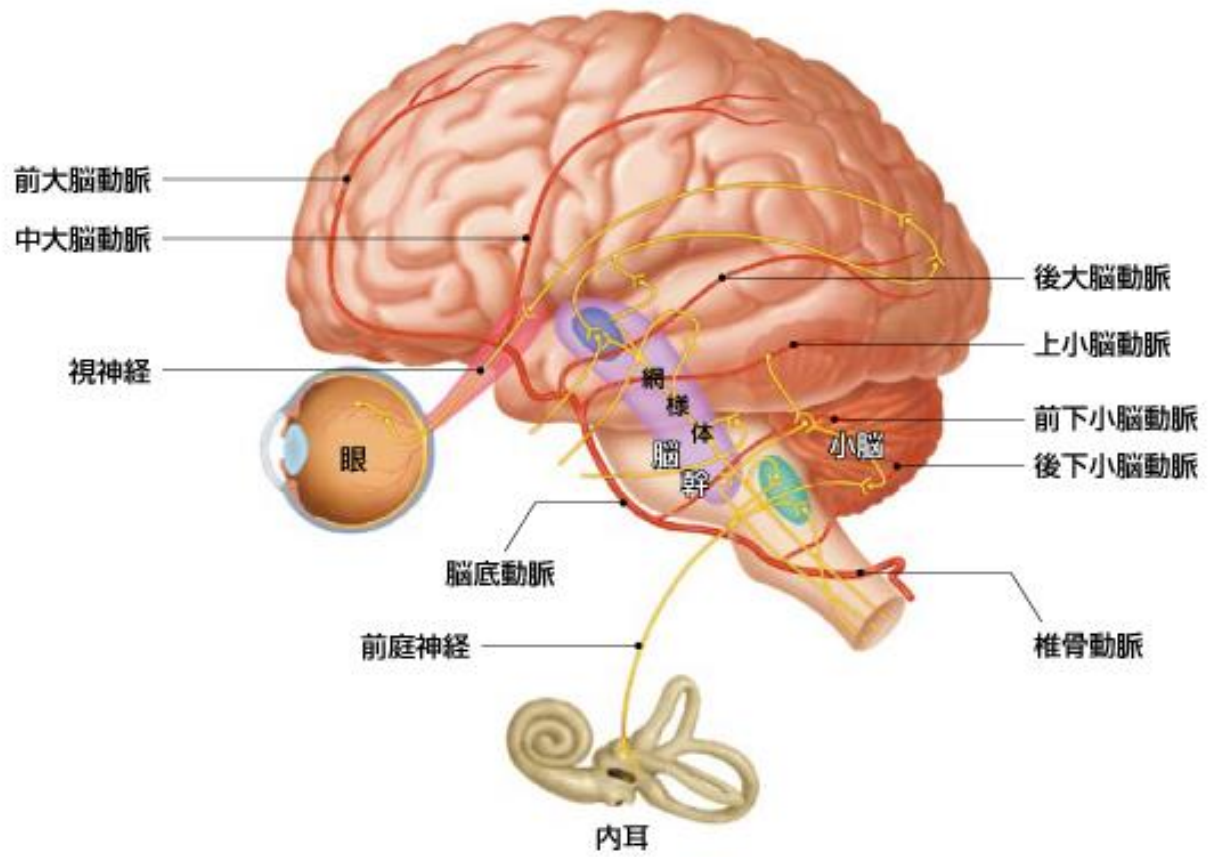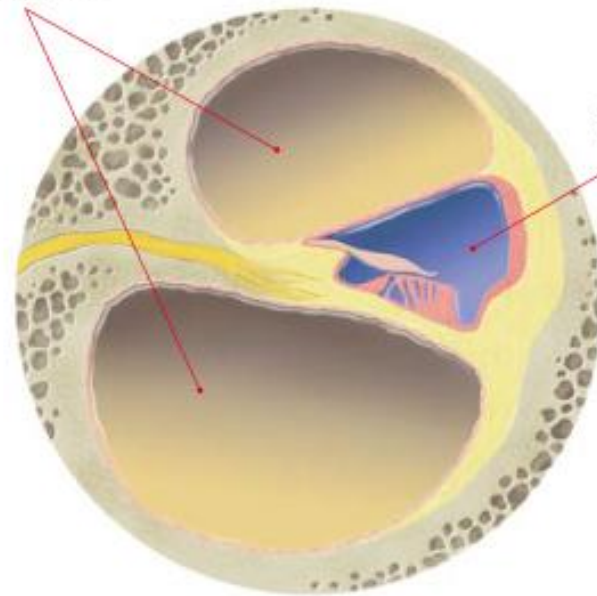


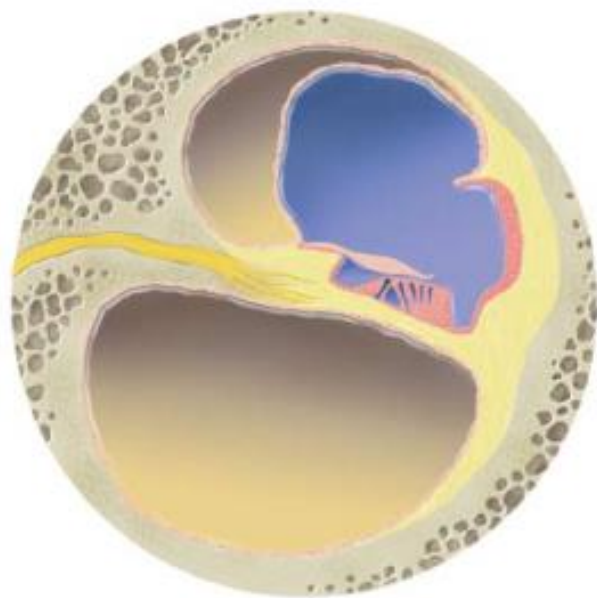


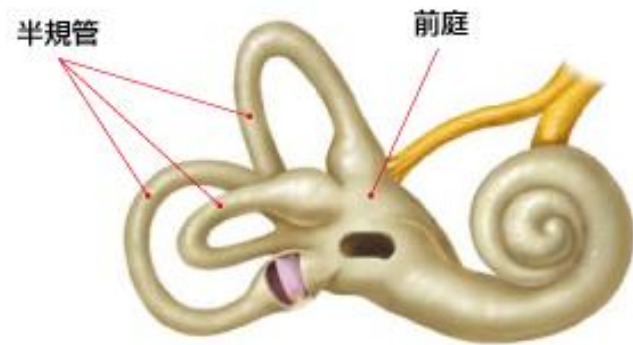
蝸牛

外リンパ腔

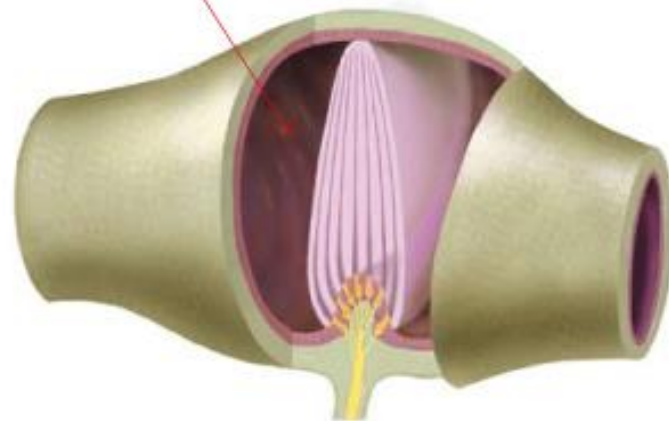


内リンパ腔

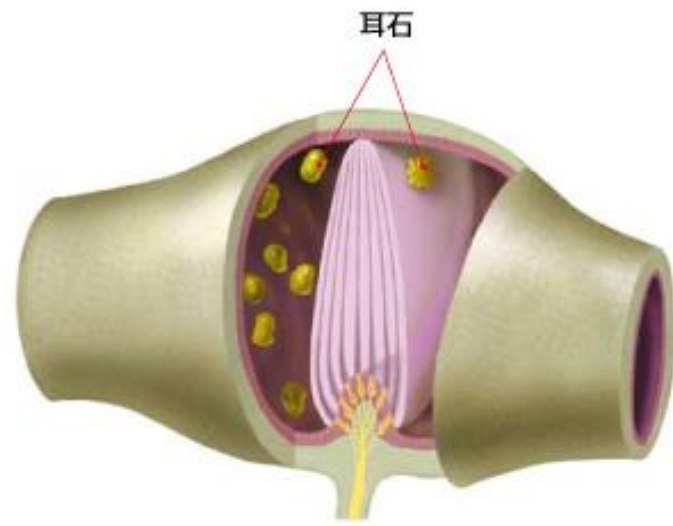




内リンパ腔



正常



耳石

疾患

